

Advanced Image Analysis to Select Patients for PSMA Radioligand Therapy and Assess Treatment Response

John M Floberg MD, PhD , Christos E Kyriakopoulos MD ,
Steve Y Cho MD

PII: S2452-1094(25)00092-2
DOI: <https://doi.org/10.1016/j.adro.2025.101805>
Reference: ADRO 101805



To appear in: *Advances in Radiation Oncology*

Received date: 4 February 2025
Accepted date: 24 April 2025

Please cite this article as: John M Floberg MD, PhD , Christos E Kyriakopoulos MD , Steve Y Cho MD , Advanced Image Analysis to Select Patients for PSMA Radioligand Therapy and Assess Treatment Response, *Advances in Radiation Oncology* (2025), doi: <https://doi.org/10.1016/j.adro.2025.101805>

This is a PDF file of an article that has undergone enhancements after acceptance, such as the addition of a cover page and metadata, and formatting for readability, but it is not yet the definitive version of record. This version will undergo additional copyediting, typesetting and review before it is published in its final form, but we are providing this version to give early visibility of the article. Please note that, during the production process, errors may be discovered which could affect the content, and all legal disclaimers that apply to the journal pertain.

© 2025 Published by Elsevier Inc. on behalf of American Society for Radiation Oncology.
This is an open access article under the CC BY-NC-ND license
(<http://creativecommons.org/licenses/by-nc-nd/4.0/>)

Advanced Image Analysis to Select Patients for PSMA Radioligand Therapy and Assess Treatment Response

Short Running Title: PSMA RLT Image Analysis and Response

John M Floberg MD, PhD,¹ Christos E Kyriakopoulos MD,² Steve Y Cho MD³

¹University of Wisconsin School of Medicine and Public Health, Department of Human Oncology

²University of Wisconsin School of Medicine and Public Health, Department of Medicine, Division of Hematology & Oncology

³University of Wisconsin School of Medicine and Public Health, Department of Radiology, Division of Nuclear Medicine

Corresponding Author: John M Floberg MD, PhD, jfloberg@humonc.wisc.edu

Conflict of Interest Disclosure:

Dr. Floberg reports research support for related work from The University of Wisconsin Prostate SPORE, NCI P50CA269011

Dr. Kyriakopoulos reports the following conflicts of interest:

Research support (for unrelated projects): Sanofi-Aventis, AstraZeneca, Bristol Meyers Squibb, ESSA Pharma, Gilead Sciences, Incyte Corporation, Merck, Madison Vaccines, EMD Serono, and Pionyr Immunopharma

Advisory Boards: Sanofi-Aventis, AVEO Pharmaceuticals, EMD Serono, Exelixis, Janssen Pharmaceuticals, Pfizer

Stock: EPIC Systems, Biogen

Dr. Cho reports no conflicts of interest related to this work.

Funding: None

Abstract

Introduction: Although quantitative imaging metrics (e.g. whole-tumor mean standardized uptake value, SUV_{mean}) are predictive of response to prostate specific membrane antigen radioligand therapy (PSMA-RLT), they are clinically underutilized. Here we present a series of patients treated with PSMA-RLT analyzed with an automated image analysis tool (TRAQinformIQ) that provides quantitative metrics and compares multiple scans.

Methods: Images from three cases were analyzed with TRAQinformIQ; a patient with an excellent PSMA-RLT response, a patient who progressed on treatment, and a patient who progressed immediately after treatment. In the first two cases pre-treatment PET/CT images were analyzed. For the second and third cases pre- and post-treatment PET/CT images were analyzed.

Results: Cases one and two demonstrate the ability of TRAQinformIQ to provide quantitative metrics from pre-treatment PET/CT scans, including PSMA SUV_{mean} , and compare different imaging modalities (PET and CT in the first case, PSMA and FDG PET in the second case). In these cases, pre-treatment metrics correlated with disease response/progression. The third case demonstrates the utility of using multiple imaging modalities (FDG and PSMA PET) to assess response/progression, and the automated tool's ability to compare these scans across multiple time points.

Conclusion: Automated image analysis tools that provide quantitative imaging metrics and comparisons between scans could be a valuable aid in evaluating patient appropriateness for RLT and assessing treatment response.

Introduction

Prostate membrane specific antigen (PSMA) radioligand therapy (RLT) improves overall survival benefit in men with metastatic castration resistant prostate cancer (mCRPC) following androgen receptor pathway inhibitor (ARPI) treatment and chemotherapy.¹ While this survival benefit is seen across many patients, a broad range of responses is seen on an individual patient level. Furthermore, real world data with PSMA-RLT have shown a median PET/CT-based progression free survival (PFS) of 6 months, which is significantly shorter than the planned treatment duration (36 weeks), and less than the radiographic PFS reported in the VISION trial (8.7 months).^{1,2} This implies that better patient selection is needed for this therapy.

Quantitative imaging metrics have strong evidence supporting their use as both prognostic and predictive biomarkers.^{3,4} For example, the mean standardized uptake value (SUV_{mean}), a measure of the average concentration of RLT within the entire tumor volume, predicts PSMA-RLT efficacy.³ The trials that led to the approval of this therapy also had imaging-based entry criteria, requiring all lesions to be PSMA avid.^{1,5,6} Thus, the real-world underperformance of PSMA-RLT may be due to selection of patients who would have been excluded from these trials, or whose disease has imaging metrics that would predict poor response. Thus, ***imaging plays an important role in patient selection but is likely underutilized.***

A primary reason why imaging metrics are not routinely used in clinical practice is that they are difficult to measure manually given that many patients being considered for PSMA-RLT have dozens of metastases. This has led to proposed simplified systems that provide a much coarser assessment of PSMA uptake, for example the PSMA-RADS system.⁷ In addition, patient-level metrics such as SUV_{mean} fail to account for inter-lesional heterogeneity, which impact treatment benefit. Automated tools that can provide patient-level and lesion-level quantitative metrics could lead to broader use of imaging metrics to assess patients for PSMA-RLT, and hence lead to better utilization and outcomes with this therapy. In addition, disease response seen on PET imaging may provide an earlier signal of treatment efficacy than more conventional means (e.g. RECIST criteria), particularly in the case of patients with bone-only metastatic disease.

Methods

We present three cases demonstrating the potential of an automated image analysis tool, TRAQinformIQ (AIQ Solutions, Madison, WI) to aid in treatment selection and assessing treatment response for PSMA-RLT. TRAQinformIQ automatically identifies and segments individual lesions based upon PET uptake and anatomical CT information using statistically optimized regional threshold accounting and machine learning algorithms.^{8,9} When comparing multiple images, the algorithm performs an articulated registration for bone lesions, and performs a multi-step process of image registration, lesion dilation, lesion clustering, and linear assignment to align soft tissue lesions.^{10,11} Lesion response between 2 PET scans using the same tracer is determined based upon repeatability measurements established from clinical studies or the literature to determine optimal site-specific thresholds to identify response versus expected variability.¹²⁻¹⁴ Although originally developed for sodium fluoride PET, TRAQinformIQ can be used with FDG and PSMA PET as well. This tool has been prospectively evaluated in 2 clinical trials, both of which showed metrics from this tool could predict progression defined by more conventional means.^{15,16} This tool has received 501(k) premarket clearance for clinical use by the FDA. Images are sent to AIQ Solutions to have this analysis performed.

Results

Case 1: High volume of PSMA positive disease with an excellent response to PSMA-RLT

The first case is an 87-year-old patient who presented for consideration of PSMA-RLT 3 years after developing mCRPC. Prior therapies for his cancer included radical prostatectomy, salvage radiotherapy, clinical trials investigating DNA vaccines combined with other immunotherapies, androgen deprivation therapy (ADT), ARPI therapy, and docetaxel. His performance status at the time of his consultation was an ECOG 1, PSA was 22, he had adequate organ function, and no major comorbidities.

A PSMA PET/CT was obtained which per the Nuclear Medicine report showed widespread PSMA avid nodal disease, as well as a few PSMA avid osseous lesions. AIQ analysis showed an **SUV_{mean} of 13.0 across all lesions** with no discordance between the PSMA PET and the attenuation correction CT (Figure 1). On an individual lesion basis, the highest SUV_{mean} was 14.5, and the lowest SUV_{mean} was 2.3. The patient had an excellent PSA response to 6 cycles of Pluvicto, and his PSA continued to respond several months after completing Pluvicto with no additional systemic therapy (Figure 1). He has experienced grade 1 xerostomia but no other toxicities and has maintained a good performance status throughout treatment and after. This case demonstrates a favorable response in a cancer with high PSMA expression (as measured by the SUV_{mean}) and good concordance between PSMA PET and CT.

Case 2: High volume of PSMA positive disease with progression on PSMA-RLT

The second case is a 67-year-old man with mCRPC, with a metastatic prostate cancer initially diagnosed 2.5 years before. He had previously undergone several therapies including salvage radiation therapy, ADT, docetaxel, enzalutamide, a clinical trial combining radium-223 and a PARP inhibitor, and multiple prior courses of external

beam radiotherapy. His PSA at the time of consultation for PSMA-RLT was 288 with a doubling time of approximately 2 months, his performance status was excellent (ECOG 0), and he had adequate organ function except for mild pancytopenia (hemoglobin 9.9 g/dL, platelets 123,000/ μ L, lymphocytes 980/ μ L). The patient had both FDG and PSMA PET/CTs performed prior to treatment, both showing widespread disease. Per the clinical Nuclear Medicine report, all FDG avid metastases were also PSMA avid with the exception of an FDG avid lymph node in the neck, most lesions showed more PSMA than FDG avidity with the exception of left humerus and T1 vertebral body metastases, and several lesions were only seen on PSMA and not FDG PET. AIQ analysis showed a low average PSMA SUV_{mean} across all lesions of 3.5. The software's comparison of PSMA PET/CT to FDG PET/CT identified 14 lesions as PSMA negative versus 54 that were PSMA positive (21% negative), but by volume only 4% of the disease was PSMA negative (Figure 2). The clinical Nuclear Medicine report notably provided more detail regarding lesions seen on both PSMA and FDG PET, but that were more tracer avid on one scan versus the other, illustrating how the clinical read and software complement each other. The patient proceeded with PSMA-RLT. While his PSA rose slightly and then stabilized through the first 3 treatments, it began rising rapidly after the 4th dose (Figure 2). Repeat FDG PET/CT obtained at the time of treatment discontinuation showed numerous new lymph nodes throughout the neck, chest, abdomen, and pelvis as well as new bone and pulmonary metastases, and progressive disease in the previously noted FDG-avid lesions. Previous lesions with PSMA avidity without FDG avidity were not seen. In sum, these findings suggest response in PSMA avid disease, and significant progression in non-PSMA avid disease, with the clinical report and TRAQinform IQ report providing complimentary information that could have identified this patient as a likely poor responder to PSMA-RLT prior to the initiation of therapy. These findings also provide an example of a poor response in a cancer with a low PSMA SUV_{mean} and a high volume of FDG-avid disease.

Case 3: Initial assessment and response assessment with PSMA and FDG PET/CT

The third case is a patient with mCRPC that produced little PSA with a predominance of pulmonary metastases. Given the low PSA, it was difficult to assess this patient's appropriateness for PSMA-RLT, and very difficult to assess treatment response. At the time the patient was evaluated for PSMA-RLT, he had been diagnosed with metastatic prostate cancer approximately 5 years prior. Previous treatments included radical prostatectomy, salvage radiotherapy, ADT, abiraterone with prednisone, and docetaxel. He had an excellent performance status (ECOG 0) and adequate organ function; his PSA was notably low at 0.12. Per the clinical nuclear medicine report, PSMA PET/CT demonstrated PSMA-avid disease with extensive involvement of the lungs as well as thoracic lymph nodes and skeleton. FDG PET/CT showed no discordance with the PSMA PET per the clinical report. TRAQinform IQ analysis showed an SUV_{mean} across all lesions of 4.3. TRAQinform IQ analysis identified 7 lesions that were FDG avid and PSMA negative, and 49 PSMA positive lesions. However, by volume 99% of the disease identified was PSMA positive (Figure 3). The patient proceeded with 6 cycles of PSMA-directed therapy. He tolerated PSMA-directed therapy with minimal xerostomia and stable blood counts and PSA. Reassessment included repeat PSMA and FDG PET/CT scans. Per the clinical nuclear medicine read, the PSMA PET/CT demonstrated

decreased uptake in existing bone lesions, a new rib metastasis, and increased uptake and number of pulmonary metastases; a possible brain metastasis was also noted and later confirmed by MRI. The FDG PET/CT demonstrated an increase in the number and extent of osseous and pulmonary metastases. Comparing the pre-treatment and post-treatment PSMA PET/CT scans, AIQ analysis noted a small number of new and worsening metastatic sites, including in the brain, and a large volume of stable or improving pulmonary or osseous metastases. Analysis of the FDG PET/CT demonstrated that the vast majority of metastatic lesions were worsening, and a small volume of new lesions (Figure 3). Based upon the FDG PET/CT the patient was determined to be progressing and a different systemic therapy was recommended, in addition to radiosurgery to brain metastases. This case demonstrates the importance of both PSMA and FDG PET/CT for both initial evaluation and treatment response in patients with poorly differentiated tumors (e.g. tumors that do not produce PSA). It also demonstrates that AIQ analysis can aid in identifying and quantify progression on follow-up imaging.

Discussion:

In this case series we have presented an image analysis tool that provides quantitative information not readily available in most clinical settings. This tool can quantify PET images on both a patient-level and individual metastasis level, compare images of different modalities to assess concordance/discordance between modalities (e.g. between CT and PET or PSMA PET and FDG PET), and compare sequential PET images to assess treatment response both qualitatively and quantitatively. As a supplement and with confirmation from clinical PET imaging review, the consolidation of information in this image analysis report, particularly quantitative data, can greatly aid in clinical decision making for patients being treated with radiopharmaceutical therapies, including selecting patients most appropriate for therapy and quantitatively assessing treatment response.

The first two cases demonstrate the ability of this tool to help select patients appropriate for PSMA-directed radiopharmaceutical therapy. The SUV_{mean} on a patient level is known to be a predictive marker of response to PSMA-directed radiopharmaceutical therapy,^{3,4} but is difficult to measure on a practical, reproducible and repeatable fashion across many scanners, readers, and institutions. The TRAQinformIQ tool readily provides this metric, and in the two cases here the SUV_{mean} proved predictive of the patients' responses to therapy. TRAQinformIQ also provides individual lesion SUV_{mean} values. This will be critical as a tool to identify specific metastases that may not respond, and that warrant extra attention on follow-up and possibly additional interventions, particularly as non-responding lesions have the potential to drive overall progression.¹⁵

The second and third cases demonstrate the strength of this tool for aiding in the assessment of treatment response. Assessing response or progression is exceptionally difficult in patients with many dozens of lesions, such as the patients presented in these two cases. While RECIST provides a formalized means to do this, focusing on a small number of index lesions will inevitably provide a limited view of response.¹⁷ This is

particularly the case for RLT, where expression of the target is expected to be heterogeneous, and response is thus also expected to be heterogeneous. Both the second and third cases demonstrate how clones expressing PSMA might respond, while those that do not express PSMA progress, as evidenced by the progression seen on the FDG PET scans. The third case demonstrates the potential difficulty in assessing response to PSMA-directed therapy, and the strength of having a software to comprehensively evaluate response for dozens of pulmonary metastases across two different imaging modalities, allowing a clinician to quickly and clearly see change across 4 separate PET/CT scans. This case also demonstrates the importance of using multiple modalities to assess response, and not relying upon imaging the same molecule being targeted with therapy, thus missing disease that does not express this target.

PET/CT imaging is a functional imaging tool with great potential to personalize therapy, for example by allowing better patient selection, and better assessment of treatment response. However, these images provide a vast amount of information that is typically underutilized. Image analysis tools like the one presented here, as a supplement to clinical imaging review, will allow these images to be used in ways not possible in current clinical workflows to help aid clinical management decisions and improve the outcomes of patients treated with radiopharmaceutical therapies.

Figure Captions

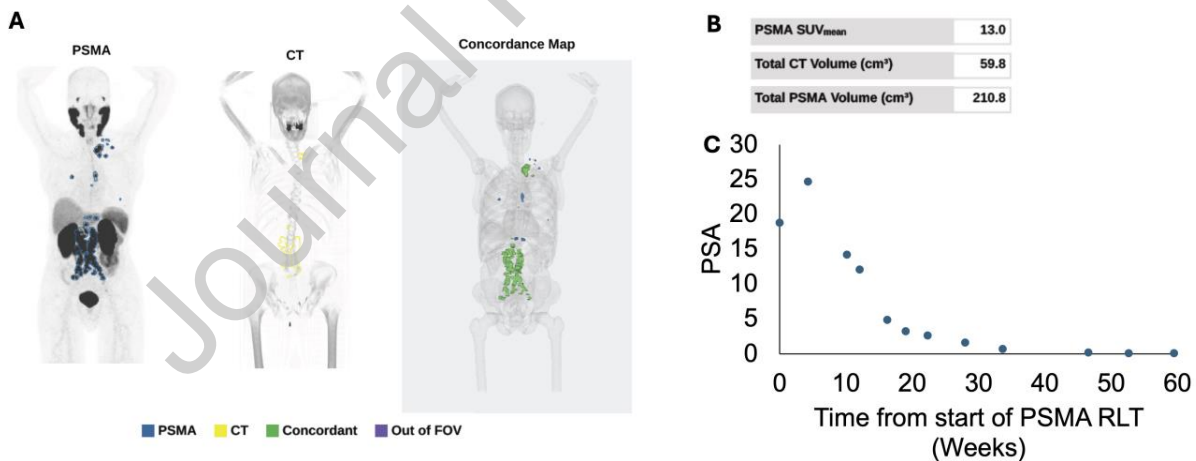


Figure 1: TRAQinformIQ analysis of patient with predominantly concordant PSMA PET (blue) and CT lesions (yellow) (concordance in green on the concordance map) (A), with a high PSMA SUV_{mean} (B), and an excellent response to therapy as evidenced by the decline in PSA since starting treatment (C).

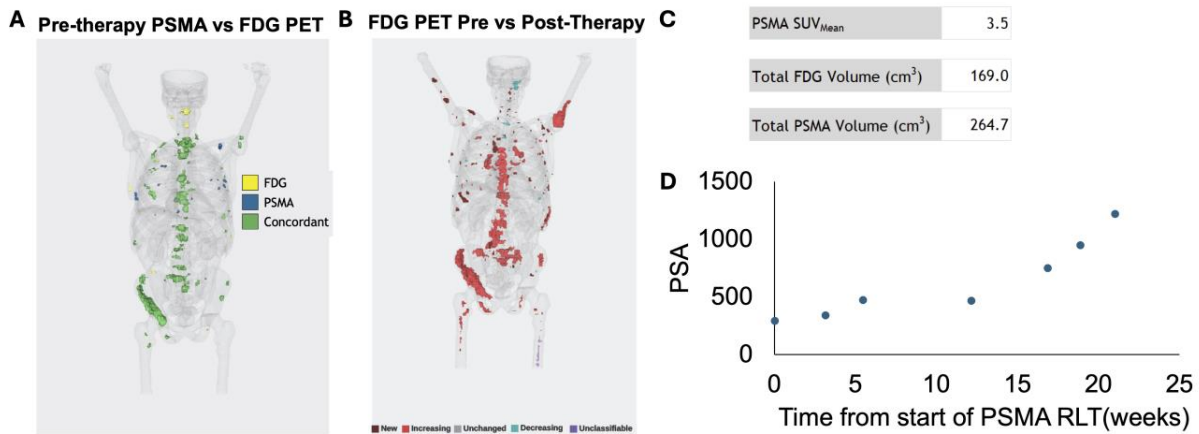


Figure 2. TRAQinformIQ analysis of a patient with a several lesions seen on FDG PET but not PSMA PET (A, yellow lesions), with a poor response to therapy with many areas of increased and new FDG uptake comparing a pre- to post-therapy scan (B, red and dark red lesions). The initial PSMA SUV_{mean} was relatively low at 3.5 (C) and the patient's PSA rose over the course of PSMA-RLT (D).

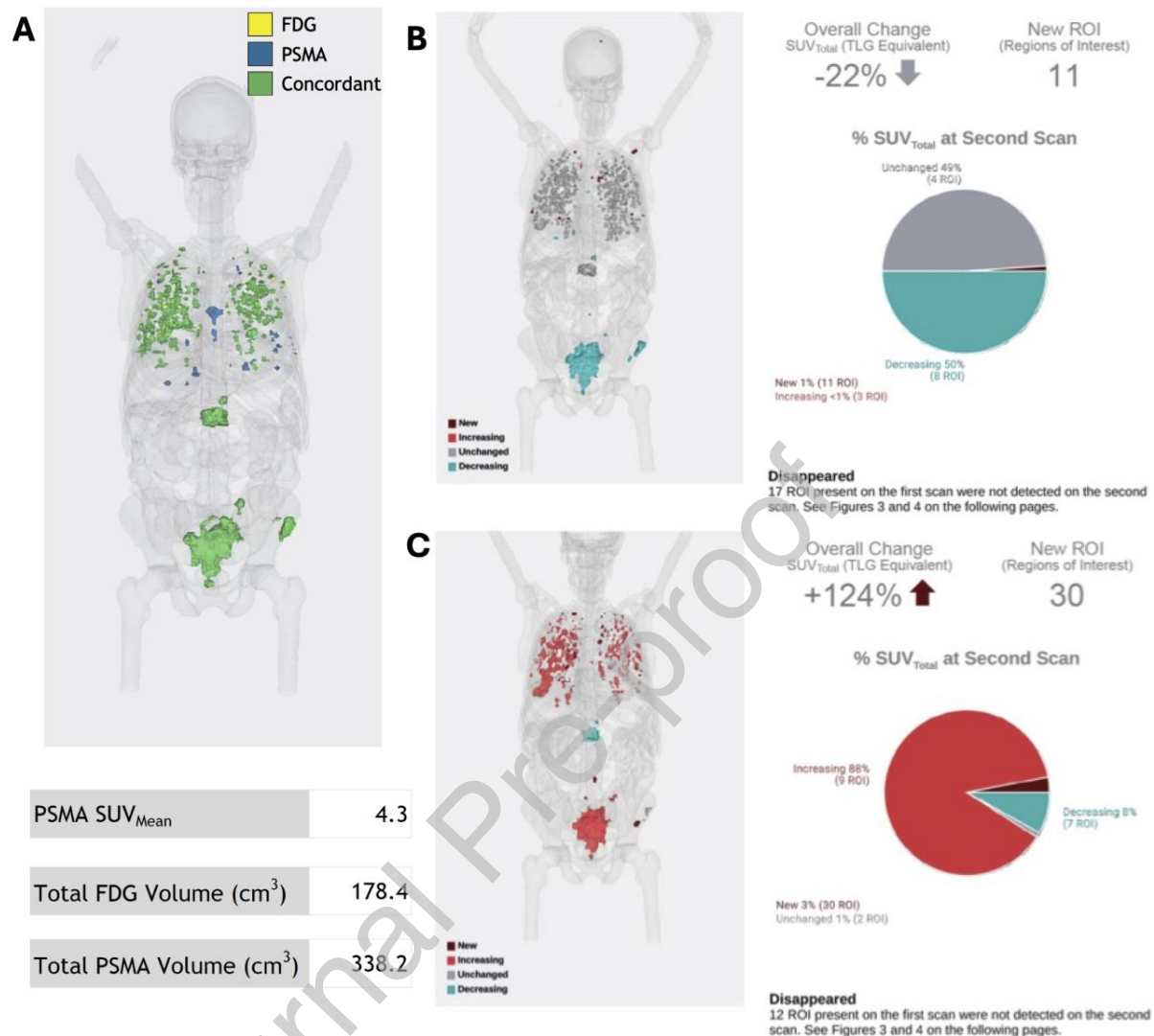


Figure 3: A patient with extensive pulmonary and osseous metastases with a cancer producing little PSA. Pre-therapy PSMA PET showed a low SUV_{mean} of 4 but overall good concordance between PSMA and FDG PET (A). Following 6 cycles of Pluvicto, overall stable disease or response was seen on follow up PSMA PET/CT (stable in gray, response in blue) (B), but comparing a pre to post-therapy FDG PET/CT clearly demonstrated progression of the vast majority of the disease (progression in red) (C).

References

1. Sartor O, de Bono J, Chi KN, et al: Lutetium-177-PSMA-617 for Metastatic Castration-Resistant Prostate Cancer. *N Engl J Med* 385:1091-1103, 2021
2. Meyrick D, Gallyamov M, Sabarimurugan S, et al: Real-World Data Analysis of Efficacy and Survival After Lutetium-177 Labelled PSMA Ligand Therapy in Metastatic Castration-Resistant Prostate Cancer. *Target Oncol* 16:369-380, 2021
3. Buteau JP, Martin AJ, Emmett L, et al: PSMA and FDG-PET as predictive and prognostic biomarkers in patients given [Lancet Oncol 23:1389-1397, 2022
4. Kuo KH, J; Rahbar, K; Kendi A; Wei, X; Bruno, F; Adra, N; Armstrong, A; Garje, R; Michalski, J; Ghebremariam, S; Brackman, M; Wong, C; Benson, T; Vogelzang, N: [68Ga]Ga-PSMA-11 PET baseline imaging as a prognostic tool for clinical outcomes to [177Lu]Lu-PSMA-617 in patients with mCRPC: A VISION substudy, American Society of Clinical Oncology. Chicago, *Journal of Clinical Oncology*, 2022
5. Hofman MS, Emmett L, Sandhu S, et al: [Lancet 397:797-804, 2021
6. Hofman MS, Emmett L, Sandhu S, et al: Overall survival with [Lancet Oncol 25:99-107, 2024
7. Rowe SP, Pienta KJ, Pomper MG, et al: PSMA-RADS Version 1.0: A Step Towards Standardizing the Interpretation and Reporting of PSMA-targeted PET Imaging Studies. *Eur Urol* 73:485-487, 2018
8. Perk T, Chen S, Harmon S, et al: A statistically optimized regional thresholding method (SORT) for bone lesion detection in. *Phys Med Biol* 63:225018, 2018
9. Weisman AJ, Kieler MW, Perlman SB, et al: Convolutional Neural Networks for Automated PET/CT Detection of Diseased Lymph Node Burden in Patients with Lymphoma. *Radiol Artif Intell* 2:e200016, 2020
10. Yip S, Perk T, Jeraj R: Development and evaluation of an articulated registration algorithm for human skeleton registration. *Phys Med Biol* 59:1485-99, 2014
11. Santoro-Fernandes V, Huff D, Scarpelli ML, et al: Development and validation of a longitudinal soft-tissue metastatic lesion matching algorithm. *Phys Med Biol* 66, 2021
12. Lin C, Bradshaw T, Perk T, et al: Repeatability of Quantitative 18F-NaF PET: A Multicenter Study. *J Nucl Med* 57:1872-1879, 2016
13. Lodge MA: Repeatability of SUV in Oncologic. *J Nucl Med* 58:523-532, 2017
14. Pollard JH, Raman C, Zakharia Y, et al: Quantitative Test-Retest Measurement of. *J Nucl Med* 61:1145-1152, 2020
15. Harmon SA, Perk T, Lin C, et al: Quantitative Assessment of Early [18F]Sodium Fluoride Positron Emission Tomography/Computed Tomography Response to Treatment in Men with Metastatic Prostate Cancer to Bone. *J Clin Oncol* 35:2829-2837, 2017
16. Kyriakopoulos CE, Heath EI, Ferrari A, et al: Exploring Spatial-Temporal Changes in. *J Clin Oncol* 38:3662-3671, 2020
17. Eisenhauer EA, Therasse P, Bogaerts J, et al: New response evaluation criteria in solid tumours: revised RECIST guideline (version 1.1). *Eur J Cancer* 45:228-47, 2009